

# Hidradenitis suppurativa and squamous cell carcinoma: a systematic review of the literature

Marcin Gierek<sup>1</sup>, Paweł Niemiec<sup>2</sup>, Karol Szyluk<sup>3,4</sup>, Gabriela Ochala-Gierek<sup>5</sup>, Beata Bergler-Czop<sup>6</sup>

<sup>1</sup>Dr Stanisław Sakiel Center for Burns Treatment, Siemianowice Śląskie, Poland

<sup>2</sup>Department of Biochemistry and Medical Genetics, Faculty of Health Sciences in Katowice, Medical University of Silesia in Katowice, Poland

<sup>3</sup>Department of Physiotherapy, Faculty of Health Sciences in Katowice, Medical University of Silesia in Katowice, Poland

<sup>4</sup>District Hospital of Orthopaedics and Trauma Surgery, Piekary Śląskie, Poland

<sup>5</sup>Dermatology Department, City Hospital, Sosnowiec, Poland

<sup>6</sup>Department of Dermatology, Medical University of Silesia, Katowice, Poland

Adv Dermatol Allergol 2023; XL (3): 350–354

DOI: <https://doi.org/10.5114/ada.2023.126563>

## Abstract

Hidradenitis suppurativa (HS) is a chronic disease which is often recurrent and occurs as abscesses of the apocrine gland. The most common locations of HS are gluteal/perianal, axillary or inguinal. It is reasonable to assume that squamous cell carcinoma may arise from HS. As researchers in the field of dermatology, HS surgery and conventional surgical oncology, we studied whether there is any correlation between HS and neoplasms. Evidence shows a correlation between HS and squamous cell carcinoma. The aim of the study was to find literature about HS and SCC and analyse potential risk factors. This is a systemic review concerning squamous cell carcinoma and hidradenitis suppurativa.

**Key words:** hidradenitis suppurativa, surgical treatment, squamous cell carcinoma.

## Introduction

Hidradenitis suppurativa (HS, acne inversa) is a chronic disease characterized by recurrent, painful, deep-seated nodules and abscesses of apocrine gland-bearing skin [1]. HS causes painful discomfort as well as social embarrassment, which has a negative influence on the quality of life [2]. A mean disease incidence of 6.0 per 100,000 person-years and an average prevalence of 1% has been reported in Europe [3]. The first reports about HS in the literature were published in 1839 by Valpeau [4]. Acne inversa (HS) also known as Hidradenitis Suppurativa or Verneuil's Disease is an inflammatory chronic disease of the hair follicle that presents with different lesions in the apocrine gland-bearing areas of the human body. Most common areas are axillae, inguinal and anogenital regions [4]. Presentation of the disease involves a classic distribution of painful lesions in the skin creases with associated local complications of abscesses and sinuses [5]. There are often systemic symptoms, and management is handled by various specialties such as dermatology, general surgery or plastic surgery. Hidradenitis suppurativa is multispecialty disease. As a result of this multidisciplinary approach to the disease, an accurate diagnosis is often delayed. The

exact aetiology remains unknown, but it is suggested to be associated with smoking, diabetes, poor hygiene, immunocompromised and reduced cutaneous levels of calprotectin, zinc, or ascorbate. Hidradenitis suppurativa is associated with several comorbidities, including diabetes mellitus and Crohn's disease. The clinical presentation of hidradenitis suppurativa ranges from rare, mild inflammatory nodules to widespread abscesses, sinus tracts, and scarring. The primary mechanism is a follicular occlusion with secondary inflammation, and destruction of the pilo-sebaceous-apocrine apparatus and extension to the adjacent subcutaneous tissue. It resulted in an inflammatory response that is associated with bacterial infection of the apocrine sweat glands [6]. Prevalence of HS has been shown to be greater in females than males [7]. Cutaneous squamous cell carcinoma (SCC) is the second most common non-melanoma skin cancer. It accounts for 20% of skin cancer cases [8]. Squamous cell carcinomas also known as epidermoid carcinomas, comprise a number of different types of cancer that result from squamous cells [9]. These cells are formed on the surface of the skin, on the lining of hollow organs in the body, and on the lining of the respiratory and digestive tracts [10].

---

**Address for correspondence:** Beata Bergler-Czop, Department of Dermatology, Medical University of Silesia, Katowice, Poland, e-mail: [bettina2@tlen.pl](mailto:bettina2@tlen.pl)

**Received:** 11.01.2023, **accepted:** 22.01.2023.

This is an Open Access article distributed under the terms of the Creative Commons Attribution-NonCommercial-ShareAlike 4.0 International (CC BY-NC-SA 4.0) License (<http://creativecommons.org/licenses/by-nc-sa/4.0/>)

The literature has documented SCC as a rare complication of chronic HS lesions. SCC development within pre-existing HS lesions has been considered to be the most severe complication of HS. Despite the extensive documentation of cases detailing SCC complicating HS lesions, the relationship between HS lesions and SCC is yet to be explored and integrated [8–10]. Early recognition of SCC in an HS patient is very important for treatment.

### Aim

The performed a literature review with the aim of identifying and summarizing the characteristics, and meta-analysis of current studies in this field.

### Material and methods

The study identification on 16 December 2021, the PubMed, Medline databases were searched using various forms of two key words: “hidradenitis suppurativa” and “squamous cell carcinoma”. We also used alternative forms of these key words: “HS”, “SCC” and “acne inversa”. The publication dates we chose were between 1900 and 2021 because most of the medical literature about Hidradenitis Suppurativa was published after 1950 (Hurley). We found 98 papers (abstracts, original texts, case reports). We excluded 53 papers. This literature review included original articles only written in the English language, study population (HS patients with SCC), case series, case reports or experimental randomized controlled trials. The analysis focused on the general characteristics of the patient (age, sex, potential risk factors such as addictions, HPV infection), on the side of characteristics of the patients with HS (age, duration of HS, Hurley Stage, location of the lesions, treatment), on the side of characteristics of patients with SCC (age at the time of diagnosis, location of SCC, stage of malignancy, metastasis, cancer treatment, mortality rate). We included 74 patients with HS and SCC. The flowchart of study selection is presented in Figure 1. The oldest case of SCC in HS was from 1964. Literature included in this review comprises 45 original papers [10–54].

### Results

All the case reports and series met minimum quality assessment standards. The identification of the data was very difficult, due to their rarity. Most of the papers were case reports, and authors had different criteria in the assessment of each case. First of all, we focused on patient demographics and general characteristics and then we examined SCC data (SCC characteristics). While a few authors did not elaborate on the histological details, patient details, and the attempted treatments, overall methodological quality of the selected articles was found to be satisfactory.

### HS patients general characteristics

A total of 74 cases were included in this analysis. General HS patients characteristics are detailed in Table 1. The majority was male patients – 85.1% (63 male cases vs. 11 female cases). The mean age of the patients was 52.67 years. HS duration time (mean) was 25.79 years. Most patients were in Hurley Stage III (Table 1). We also focused on risk factors, which could potentially play a role in neoplastic processes. Risk factors such as smoking, obesity, HPV infection, HIV, Crohn’s disease were included in our analysis. Only 5 patients were reported to be using immunosuppressive systemic therapy for HS.

### SCC general characteristics

We analysed the location of SCC on the HS lesions. The majority was located in the gluteal/perianal region (94.59%). The most common morphology was tumour and ulcer on the HS lesion. We also focused on metastatic status where we found that 62.8% of included patients have no metastatic data. We also took into consideration the mortality rates and no recurrence rate with follow-up consultation with the patients (6 months, 12 months, 18 months, 24 months, 36 months, 4 years, 25 years). General characteristics of SCC in HS patients are shown in Table 2.

### Associations/risk factors

The average age of the patient with SCC in HS lesions was 52.6 years. The mean time from onset of HS to SCC was 25.79 years (range 8 years to 53 years). Majority of the patients was in Hurley Stage III (97.2%). The most frequent region where SCC was located on the HS lesion was perianal/gluteal area (94.59%). Patients rarely presented with HS in the inguinal and axillary region 36%

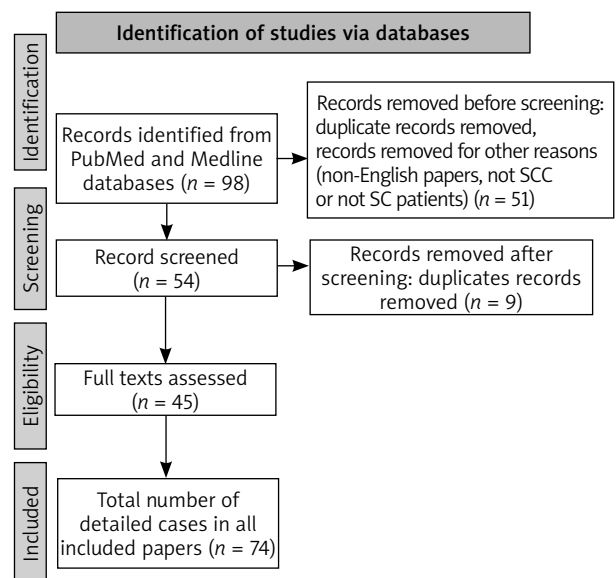


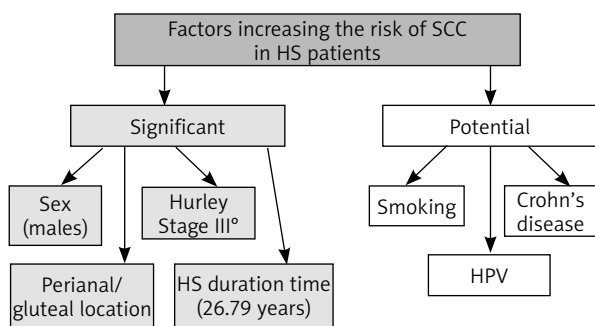
Figure 1. Flowchart of the study selection

**Table 1.** Hidradenitis suppurativa patients profile

Characteristics of SCC		Number of patients	Percentage of cases (%)
Sex	Males	63	85
	Females	11	15
	Total	74	100
Age, mean [years] (range)	52.67 (28–78)	–	–
HS duration time (range) [years]	8–53	–	–
Mean HS duration time to SCC diagnosis [years]	25.79	–	–
Hurley Stage (n = 36)	I	0	–
	II	1	2.8
	III	35	97
Risk factors (n = 25)	HPV	9	36
	Smoking	6	24
	Diabetes	3	12
	Crohn's disease	3	12
	HIV	2	8
	Obesity	2	8
HS treatment (n = 54)	Antibiotics	27	50
	Surgical	22	41
	Biological	5	9

**Table 2.** General characteristics of SCC

Characteristics of SCC		Number of patients	Percentage of cases (%)
Location of SCC on HS lesions (n = 74 patients)	Gluteal/perianal	70	94.6
	Inguinal	3	4.1
	Axillary	1	1.4
Morphology (n = 36 patients)	Tumour	22	61.1
	Ulcer	13	36.1
	Nodule	1	2.8
Metastatic status (n = 43 patients)	No metastases	27	62.8
	Metastases	16	37.2
SCC treatment (n = 54 patients)	Surgical excision	31	57.4
	Radiotherapy	20	37
	Chemotherapy	3	5.6
Mortality and recurrence rate (n = 50 patients)	Mortality	20	40
	No recurrence (follow-up)	30	60
No recurrence for a certain period	6 months	5	10
	12 months	4	8
	18 months	3	6
	24 months	13	26
	36 months	3	6
	4 years	1	2
	25 years	1	2



**Figure 2.** Factors that increase the risk of SCC in HS patients

of the patients were HPV positive and 24% were smokers. 12% were diabetic, and 12% also had Crohn's disease. We divided risk factors that increase the risk of SCC in HS to a) significant and b) potential which is presented in Figure 2.

**Discussion**

SCC is the second most common skin cancer [8]. The most important risk factors for the development of SCC are

sun exposure, age and type of the skin. It is also described in chronic wounds [55–61]. Immunosuppression is one of the risk factors. Some of the authors described mutation in the suppressor protein (TP53) [62]. Pathogenesis of SCC arising in the sun exposed regions seems to be improper in HS patients. Most of the lesions are located in the gluteal and perianal region. The development of SCC is multifactorial. HS is more prevalent in women, but SCC transformation is more frequent in men [15, 17]. SCC in HS is frequently located in the perineal and gluteal areas. These areas are exposed to bacterial, fungal, or viral infections and could promote chronic inflammation and thus result in the occurrence of SCC. HPV was present in 8 genital or anal tumours; among them, HPV-16 (high risk) was present in 7 cases. HPV may be an important contributory factor to SCC arising in HS. Of the 74 published cases analysed in this study, SCC almost always occurred in males with Hurley Stage III and long-standing gluteal/perianal HS. Evidence of HPV was demonstrated in 36% of tested patients.

The nonavalent HPV vaccine (°Gardasil-9) is approved for the prevention of HPV-related mucosal cancers in women ≤ 45 and men ≤ 26 years of age, and there is no doubt that should be considered as a prevention of SCC [63]. Flores *et al.* noted a significant positive correlation

of HPV-16 viral load between proximal anatomic sites in the anogenital region of men, suggesting a possible autoinoculation in male HPV HS patients, facilitated by humidity and inadequate hygiene due to chronic pain in the affected area [64]. Immunosuppressive therapies can possibly cause cancers, but in our analysis, we found only 5 cases with such a therapy. Smoking is also a potential risk factor which often occurs in SCC HS patients.

## Conclusions

We suggest that the most significant risk factors in HS patients are sex (males), long HS duration time, perianal/gluteal region, and Hurley Stage III. Considering the high mortality rate (40%), we suggest screening/examining SCC lesions in all HS patients for SCC. The potential risk factors such as males, Hurley Stage III, long HS duration time and location of HS in the perianal/gluteal region should be considered. As HS is a chronic skin disease with the possibility of SCC occurring in these lesions, we should be encouraged to adopt surgical rather than conservative dermatological treatment.

## Conflict of interest

The authors declare no conflict of interest.

## References

- Fimmel S, Zouboulis CC. Comorbidities of hidradenitis suppurativa (acne inversa). *Dermatoendocrinology* 2010; 2: 9-16.
- Bergler-Czop B, Hadasik K, Brzezińska-Wcisło L. Acne inversa: difficulties in diagnostics and therapy. *Adv Dermatol Allergol* 2015; 32: 296-301.
- Zouboulis CC, Desai N, Emtestam L, et al. European S1 guideline for the treatment of hidradenitis suppurativa/acne inversa. *J Eur Acad Dermatol Venereol* 2015; 29: 619-44.
- Narla S, Lyons AB, Hamzavi LH. The most recent advances in understanding and managing hidradenitis suppurativa. *F1000Res* 2020; 9: F1000. doi: 10.12688/f1000research.26083.1
- Cartron A, Driscoll MS. Comorbidities of hidradenitis suppurativa: a review of the literature. *Int J Womens Dermatol* 2019; 5: 330-4.
- Revuz J. Hidradenitis suppurativa. *J Eur Acad Dermatol Venereol* 2009; 23: 985-98.
- Hurley HJ. Diseases of the eccrine sweat glands. In: *Dermatology*. 3rd ed. Moschella SL, Hurley HJ (eds.). Philadelphia, Saunders USA, 1992; 2: 1514-37.
- Chapman S, Delgadillo D, Barber C, Khachemoune A. Cutaneous squamous cell carcinoma complicating hidradenitis suppurativa: a review of the prevalence, pathogenesis, and treatment of this dreaded complication. *Acta Dermatovenereol Alp Pannonica Adriat* 2018; 27: 25-8.
- Waldman A, Schmults C. Cutaneous squamous cell carcinoma. *Hematol Oncol Clin North Am* 2019; 33: 1-12.
- Pena ZG, Sivamani RK, Konia TH, Eisen DB. Squamous cell carcinoma in the setting of chronic hidradenitis suppurativa: report of a patient and update of the literature. *Dermatol Online J* 2015; 21: 13030/qt9q9707dp.
- Özkur E, Altunay İK, Celayir MF, et al. A giant squamous cell carcinoma arising in a patient with hidradenitis suppurativa. *Adv Skin Wound Care* 2020; 33: 554-56.
- Juviler PG, Patel AP, Qi Y. Infiltrative squamous cell carcinoma in hidradenitis suppurativa: a case report for early surgical intervention. *Int J Surg Case Rep* 2019; 55: 50-3.
- Barresi V, Vitarelli E, Barresi G. Acne inversa complicated by squamous cell carcinoma in association with diffuse malignant peritoneal mesothelioma arising in the absence of predisposing factors: a case report. *J Cutan Pathol* 2008; 35: 70-3.
- Ben AJ, Bouasker I, Najah H, et al. Squamous cell carcinoma arising in Verneuil's disease. *Tunis Med* 2008; 86: 169-70.
- Jourabchi N, Fischer AH, Cimino-Mathews A, et al. Squamous cell carcinoma complicating a chronic lesion of hidradenitis suppurativa: a case report and review of the literature. *Int Wound J* 2017; 14: 435-8.
- Scheinfeld N. A case of a patient with stage III familial hidradenitis suppurativa treated with 3 courses of infliximab and died of metastatic squamous cell carcinoma. *Dermatol Online J* 2014; 20: doj\_21764.
- Lavogiez C, Delaporte E, Darras-Vercambre S, et al. Clinicopathological study of 13 cases of squamous cell carcinoma complicating hidradenitis suppurativa. *Dermatology* 2010; 220: 147-53.
- Grewal NS, Wan DC, Roostaeian J, Rubayi SR. Marjolin ulcer in hidradenitis suppurativa: case reports. *Ann Plast Surg* 2010; 64: 315-7.
- Kohorst JJ, Shah KK, Hallemeier CL, et al. Squamous cell carcinoma in perineal, perianal, and gluteal hidradenitis suppurativa: experience in 12 patients. *Dermatol Surg* 2019; 45: 519-26.
- Chandramohan K, Mathews A, Kurian A, et al. Squamous cell carcinoma arising from perineal lesion in a familial case of hidradenitis suppurativa. *Int Wound J* 2009; 6: 141-4.
- Chang JB, Kung TA, Cederna PS. Acute Marjolin's ulcers: a nebulous diagnosis. *Ann Plast Surg* 2014; 72: 515-20.
- Huang C, Lai Z, He M, et al. Successful surgical treatment for squamous cell carcinoma arising from hidradenitis suppurativa: a case report and literature review. *Medicine (Baltimore)* 2017; 96: e5857.
- Pérez-Díaz D, Calvo-Serrano M, Martínez-Hijosa E, et al. Squamous cell carcinoma complicating perianal hidradenitis suppurativa. *Int J Colorectal Dis* 1995; 10: 225-8.
- Sevray M, Dupré PF, Le Flahec G, et al. Vulvar squamous cell carcinoma complicating hidradenitis suppurativa in a young woman. *JAAD Case Rep* 2019; 5: 999-1001.
- Mendonça H, Rebelo C, Fernandes A, et al. Squamous cell carcinoma arising in hidradenitis suppurativa. *J Dermatol Surg Oncol* 1991; 17: 830-2.
- Altunay İK, Gökdemir G, Kurt A, Kayaoglu S. Hidradenitis suppurativa and squamous cell carcinoma. *Dermatol Surg* 2002; 28: 88-90.
- Maclean GM, Coleman DJ. Three fatal cases of squamous cell carcinoma arising in chronic perineal hidradenitis suppurativa. *Ann R Coll Surg Engl* 2007; 89: 709-12.
- Shukla VK, Hughes LE. A case of squamous cell carcinoma complicating hidradenitis suppurativa. *Eur J Surg Oncol* 1995; 21: 106-9.
- Yen CF, Chang Y, Lee YY. Image gallery: squamous cell carcinoma arising in long-standing hidradenitis suppurativa. *Br J Dermatol* 2018; 179: e226.
- Atri S, Ben Mahmoud A, Zehani A, et al. The management of hidradenitis suppurativa degenerating into squamous cell

- carcinoma: about three case reports. *Ann Med Surg (Lond)* 2021; 64: 102239.
31. Cooper SD, Coudrey MCE, Linos KD, et al. Squamous cell carcinoma in hidradenitis suppurativa lesions following tumor necrosis factor  $\alpha$  inhibitors. *Cutis* 2021; 107: E5-7.
  32. Dessinioti C, Plaka M, Zisimou C, et al. Advanced squamous cell carcinoma of the axillae mimicking hidradenitis suppurativa. *J Eur Acad Dermatol Venereol* 2017; 31: e421-3.
  33. Herschel S, Laske J, Stein A. Squamous cell carcinoma arising in hidradenitis suppurativa. *J Dtsch Dermatol Ges* 2014; 12: 417-9.
  34. Yatim A, Bohelay G, Grootenboer-Mignot S, et al. Paraneoplastic pemphigus revealed by anti-programmed death-1 pembrolizumab therapy for cutaneous squamous cell carcinoma complicating hidradenitis suppurativa. *Front Med (Lausanne)* 2019; 6: 249.
  35. Rosenzweig LB, Brett AS, Lefaivre JF, Vandersteenhoven JJ. Hidradenitis suppurativa complicated by squamous cell carcinoma and paraneoplastic neuropathy. *Am J Med Sci* 2005; 329: 150-2.
  36. Giesey R, Delost GR, Honaker J, Korman NJ. Metastatic squamous cell carcinoma in a patient treated with adalimumab for hidradenitis suppurativa. *JAAD Case Rep* 2017; 3: 489-91.
  37. Joglekar K, Jackson C, Kadaria D, Sodhi A. Metastatic squamous cell carcinoma of the pleura: a rare complication of hidradenitis suppurativa. *Am J Case Rep* 2016; 17: 989-92.
  38. Donsky HJ, Mendelson CG. Squamous cell carcinoma as a complication of hidradenitis suppurativa. *Arch Dermatol* 1964; 90: 488-91.
  39. Lee SJ, Lim JM, Lee SH, et al. Invasive cutaneous squamous cell carcinoma arising from chronic hidradenitis suppurativa: a case report of treatment by slow mohs micrographic surgery. *Ann Dermatol* 2021; 33: 68-72.
  40. Rekawek P, Mehta S, Andikyan V, et al. Squamous cell carcinoma of the vulva arising in the setting of chronic hidradenitis suppurativa: a case report. *Gynecol Oncol Rep* 2016; 16: 28-30.
  41. Verdelli A, Antiga E, Bonciani D, et al. A fatal case of hidradenitis suppurativa associated with sepsis and squamous cell carcinoma. *Int J Dermatol* 2016; 55: e52-3.
  42. Hessam S, Sand M, Bechara FG. When inflammation shifts to malignancy: extensive squamous cell carcinoma in a female hidradenitis suppurativa/acne inversa patient. *J Dtsch Dermatol Ges* 2017; 15: 86-8.
  43. Li M, Hunt MJ, Commens CA. Hidradenitis suppurativa, dowling degos disease and perianal squamous cell carcinoma. *Australas J Dermatol* 1997; 38: 209-11.
  44. Pitch MA, Bryan DJ, McMillan J, et al. A fatal case of parathyroid hormone-related peptide (PTHrP)-producing squamous cell carcinoma arising in the context of long-standing hidradenitis suppurativa. *JAAD Case Rep* 2018; 4: 426-8.
  45. Short KA, Kalu G, Mortimer PS, Higgins EM. Vulval squamous cell carcinoma arising in chronic hidradenitis suppurativa. *Clin Exp Dermatol* 2005; 30: 481-3.
  46. Gur E, Neligan PC, Shafir R, et al. Squamous cell carcinoma in perineal inflammatory disease. *Ann Plast Surg* 1997; 38: 653-7.
  47. Pagliarello C, Paradisi A. The perils of a defective medical communication: fatal neglected squamous cell carcinoma arising in perineal hidradenitis suppurativa. *Case Rep Dermatol* 2011; 3: 5-7.
  48. Gordon SW. Squamous cell carcinoma arising in hidradenitis suppurativa: case report. *Plast Reconstr Surg* 1977; 60: 800-2.
  49. Losanoff JE, Sochaki P, Khoury N, et al. Squamous cell carcinoma complicating chronic suppurative hidradenitis. *Am Surg* 2011; 77: 1449-53.
  50. Malaguarnera M, Pontillo T, Pistone G, Succi L. Squamous-cell cancer in Verneuil's disease (hidradenitis suppurativa). *Lancet* 1996; 348: 1449.
  51. McArdle DJT, McArdle JP, Lee F, Mignanelli ED. Rare "inverted" verrucous carcinoma (carcinoma cuniculatum) of the sacrogluteal region: case report and literature review. *Int J Surg Pathol* 2017; 25: 438-42.
  52. Black SB, Woods JE. Squamous cell carcinoma complicating hidradenitis suppurativa. *J Surg Oncol* 1982; 19: 25-6.
  53. Rosen T. Squamous cell carcinoma: complication of chronic skin disorders in black patients. *J Natl Med Assoc* 1986; 78: 1203-5.
  54. Katz RD, Goldberg NH. Marjolin ulcer arising within hidradenitis: a case report and literature review. *Ann Plast Surg* 2009; 62: 173-4.
  55. Nijhawan PK, Elkin PL. 59-year-old man with right hip pain. *Mayo Clin Proc* 1998; 73: 541-4.
  56. Yon JR, Son JD, Fredericks C, et al. Marjolin's ulcer in chronic hidradenitis suppurativa: a rare complication of an often neglected disease. *J Burn Care Res* 2017; 38: 121-4.
  57. Beard CJ, Gathings RM, Bandino JP. Exophytic mass arising within hidradenitis suppurativa: answer. *Am J Dermatopathol* 2019; 41: 235-6.
  58. Novick M, Gard DA, Hardy SB, Spira M. Burn scar carcinoma: a review and analysis of 46 cases. *J Trauma* 1977; 17: 809-17.
  59. Knackstedt TJ, Collins LK, Li Z, et al. Squamous cell carcinoma arising in hypertrophic lichen planus: a review and analysis of 38 cases. *Dermatol Surg* 2015; 41: 1411-8.
  60. Boozalis E, Shah AA, Wigley F, et al. Morphea and systemic sclerosis are associated with an increased risk for melanoma and nonmelanoma skin cancer. *J Am Acad Dermatol* 2019; 80: 1449-51.
  61. Xiang F, Lucas R, Hales S, Neale R. Incidence of nonmelanoma skin cancer in relation to ambient UV radiation in white populations, 1978-2012: empirical relationships. *JAMA Dermatol* 2014; 150: 1063-71.
  62. Wikonkal NM, Brash DE. Ultraviolet radiation induced signature mutations in photocarcinogenesis. *J Investig Dermatol Symp Proc* 1999; 4: 6-10.
  63. Mejilla A, Li E, Sadowski CA. Human papilloma virus (HPV) vaccination: questions and answers. *Can Pharm J* 2017; 150: 306-15.
  64. Flores R, Lu B, Beibei L, et al. Correlates of human papillomavirus viral load with infection site in asymptomatic men. *Cancer Epidemiol Biomarkers Prev* 2008; 17: 3573-6.